

Blue and Red Light Combination LED Phototherapy for Acne Vulgaris in Patients with Skin Phototype IV

Seung Yoon Lee, MD, Chung Eui You, MD, and Mi Youn Park, MD, PhD*

Department of Dermatology, National Medical Center, Seoul, Republic of Korea

Background and Objectives: Blue light is effective for acne treatment, inducing photodynamic destruction of *Propionibacterium acnes* (*P. acnes*). This study was designed to investigate the efficacy of combined blue and red light-emitting diode (LED) phototherapy for acne vulgaris.

Materials and Methods: Twenty-four patients with mild to moderately severe facial acne were treated with quasimonochromatic LED devices, alternating blue (415 nm) and red (633 nm) light. The treatment was performed twice a week for 4 weeks. Objective assays of the skin condition were carried out before and after treatment at each treatment session. Clinical assessments were conducted before treatment, after the 2nd, 4th, and 6th treatment sessions and at 2, 4, and 8 weeks after the final treatment by grading and lesion counting.

Results: The final mean percentage improvements in non-inflammatory and inflammatory lesions were 34.28% and 77.93%, respectively. Instrumental measurements indicated that the melanin levels significantly decreased after treatment. Brightened skin tone and improved skin texture were spontaneously reported by 14 patients.

Conclusion: Blue and red light combination LED phototherapy is an effective, safe and non-painful treatment for mild to moderately severe acne vulgaris, particularly for papulopustular acne lesions. *Lasers Surg. Med.*

© 2006 Wiley-Liss, Inc.

Key words: acne treatment; light-emitting diodes; light therapy

INTRODUCTION

Acne is one of the most common skin conditions and accounts for more than 30% of all visits to dermatologists [1–3]. Topical and systemic antibiotics, retinoids, and chemical peelings have been used conventionally for acne treatment with variable success rates [4–6]. However, a recent increase in the antibiotics resistance of *Propionibacterium acnes* (*P. acnes*) and adverse effects of systemic retinoids and antibiotics are becoming obstacles to acne treatment, thus making physicians seek novel treatment modalities [7–13].

Recently, it has been revealed that visible light activates the endogenous porphyrins of *P. acnes*, which results in a photodynamic reaction to destroy the bacteria [14–23]. The absorption peak of the bacterial porphyrins is at 415 nm, which falls into the blue light waveband [15]. Many clinical

studies have demonstrated the efficacy of blue light phototherapy for acne with various success rates [24–31].

In the present study, we investigated the efficacy of combination phototherapy utilizing blue and red light-emitting diodes (LEDs) for acne vulgaris. We also measured the differences in the moisture levels, the sebum levels, and the melanin levels between before and after each treatment to investigate the effects of this therapy on the general skin condition.

MATERIALS AND METHODS

Patients

Twenty-seven patients of both sexes with mild to moderately severe facial acne were recruited for this study. The exclusion criteria were: the use of any topical acne treatment or systemic antibiotics within the 2 weeks previous to the trial; the use of systemic retinoids within the 3 months before the study; a history of photosensitivity or the recent use of photosensitizing drugs; any other skin disease that could interfere with the assessment of the acne or other systemic diseases which could affect the severity of acne by themselves or by any medicine prescribed for their treatment; a history of the use of systemic steroids; any change in the use of oral contraceptive pills or anti-inflammatory drugs within the 3 months previous to the study; pregnant or lactating women; and subjects who were likely to show poor compliance with the protocol. All patients who were eligible to participate in this study gave their informed consent for the use of an institutional review board-approved protocol and signed a consent form both for the treatment and for the clinical photography.

Light Source

The phototherapy system used as the light source for this study consisted of a base and interchangeable heads emitting quasimonochromatic light of each different preset wavelength from adjustable planar arrays of LEDs. The head emitting blue light (Omnilux blue™, Photo Therapeutics Ltd., Fazeley, UK) comprised five articulated

*Correspondence to: Mi Youn Park, MD, PhD, Department of Dermatology, National Medical Center, 18-79 Euljiro 6-ga, Jungku, Seoul 100-799, Republic of Korea.

E-mail: drlsy96@hotmail.com

Accepted 22 August 2006

Published online in Wiley InterScience

(www.interscience.wiley.com).

DOI 10.1002/lsm.20412

panels containing 260 LEDs each, so that they could be adjusted to fit the contour of the patient's face optimally. The red light head (Omnilux reviveTM, Photo Therapeutics Ltd.) consisted of four panels containing 420 LEDs each arranged in the same way. The treatment heads delivered symmetrical peak wavelengths; 415 ± 5 nm for the blue light and 633 ± 6 nm for the red light. The irradiance was 40 mW/cm^2 for the blue light and 80 mW/cm^2 for the red light at a distance of 1–10 cm from the light source. The radiant fluences, or doses, during a single treatment for 20 minutes were 48 and 96 J/cm^2 for the blue and red treatment heads, respectively.

Study Design

The patients visited our clinic with all make-up removed and rested in a stable environment for about 15 minutes. Evaluation of the severity of the acne by grading and lesion counting was then performed and a dermatologist carried out objective instrumental measurements of the moisture level, the sebum level, and the melanin level of the patient's facial skin. After the measurements, each patient washed his or her face with a gentle soap and was treated for 20 minutes in the supine position. The irradiating head was positioned about 3–5 cm above from the patient's nose, and the articulated panels comprising the head were adjusted to match the contour of the patient's face. Goggles were worn during the treatment to protect the retinae from direct illumination. When the treatment was over, the instrumental measurements were done in the same way as before treatment, which signaled the end of one treatment session. In this manner, the therapy was performed twice a week for 4 weeks and a 3–4 days' interval between each session, with the 415 nm blue treatment head being used for the first treatment session followed by the 633 nm red treatment head for the second session each week.

Clinical Assessment

Clinical assessment was conducted seven times; before treatment, after the 2nd, 4th, and 6th session during the treatment period and at 2, 4, and 8 weeks after the final treatment. The acne severity was assessed with the acne grading criteria defined by Burton et al. [3] (Table 1).

TABLE 1. The Grading Criteria of Acne Severity Defined by Burton et al. [3]

Grade	Types of lesions
Grade 0	No acne lesions
Grade 1	Sub-clinical acne: A few insignificant comedones which can be seen only on careful inspection
Grade 2	Mild acne: A few comedones and a few small papules or pustules are seen
Grade 3	Moderate acne: Prominent papules or pustules are easily recognized
Grade 4	Severe acne: Cysts are often found
Grade 5	Extremely severe acne: Widespread inflammatory lesions and many large pustule or cysts are found

The number of lesions was counted individually by lesion type at each assessment as follows: closed comedones, open comedones, papules, pustules, and nodules or cysts. Acne scars were also counted. Clinical photos of the front and bilateral sides of the subject's face were taken each time. All assessments were performed by the same physician.

The investigator's and the subject's global assessments were performed five times; before treatment, after the fourth treatment as a mid-point evaluation, and at 2, 4, and 8 weeks after the final treatment. The subject's assessment was rated on a six-point scale (worse, no change, fair, good, and excellent), and the investigator's assessment was rated on a five-point scale (represented as the percentage improvement in lesion count, worse: $\leq -10\%$, no change: $-9\% - 9\%$, mild improvement: $10\% - 39\%$, moderate improvement: $40\% - 59\%$, marked improvement: $60\% - 89\%$, and clearance: $\geq 90\%$). Patients were also asked about any symptoms or signs of adverse effects at the end of each treatment session.

Instrumental Measurement

The moisture level, the sebum level, and the melanin level were measured in numerical values using a CorneometerTM (Courage+Khazaka, Köln, Germany), a SebometerTM (Courage+Khazaka), and a MexameterTM (Courage+Khazaka), respectively. The measurements before treatment were carried out after a 15 minutes' stabilizing period to exclude any possible influences of outdoor activity on the skin condition, for example by sweating or flushing. The same part of the right malar area was chosen for the measurement every time to exclude any site-variation bias. The measurements were performed repeatedly at 10 minutes after the end of treatment to exclude any possible effects of mild heat from the phototherapy device on the measured values.

Statistical Analysis

Repeated measures of analysis of variance (RM-ANOVA) were used to evaluate the significance of the mean percentage reduction in the non-inflammatory (closed and open comedones) and the inflammatory (papules, pustules, and nodules or cysts) lesion counts between baseline and subsequent assessments. The differences between before and after treatment in the moisture, sebum, and melanin levels were analyzed using sign rank tests with the medians. Additionally, the differences in the melanin levels were also analyzed separately according to the wavelengths of light, namely blue and red light, using the same statistical method.

RESULTS

Patient Characteristics

Twenty-four (4 males and 20 females) patients out of 27 completed the study. (Two of the patients gave up the study because of personal reasons and one due to a schedule conflict. Their data were excluded from all data analysis.) The average age was 22.5 years (ranging between 18 and 30 years) and the Fitzpatrick's skin phototypes were IV in

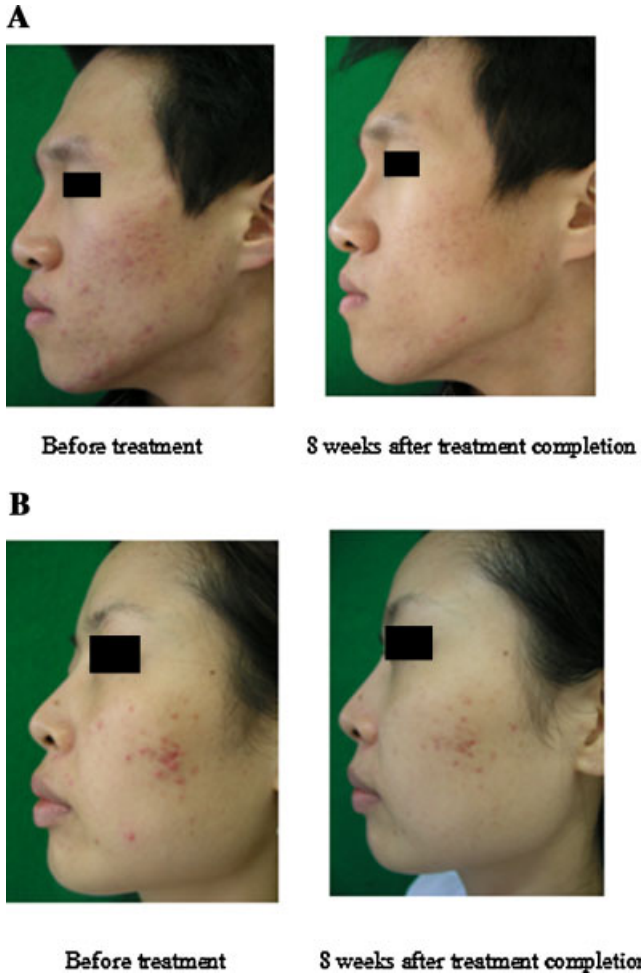


Fig. 1. Improvement of the acne lesions is shown in a 23-year-old man (A) and a 28-year-old woman (B).

all of the subjects. Sixteen patients (66.67%) had not been treated for their acne before, 4 had received oral antibiotics, 1 had received oral retinoids, and 3 had had their acne lesions extracted.

At baseline, the Burton grades were grade 3 for 11 patients, grade 4 for 5, and grade 5 for 8. The mean numbers of each lesion type were 38.54 for closed comedones, 9.46 for open comedones, 28.92 for papules, 6.46 for pustules, and 1.04 for nodules or cysts.

Clinical Efficacy

A significant improvement of facial acne was observed after treatment compared to the baseline (Fig. 1). The number of patients with Burton grade 5 steadily decreased throughout the whole study period to a statistically significant level (P -value <0.05), and was reduced to two patients at the final assessment point. The Burton grades of four patients had dropped down to grade 2 at the last evaluation.

The mean percentage reduction in non-inflammatory lesions is shown in Figure 2. There was a statistically significant reduction at every time point when compared with the baseline ($P<0.05$). At week 4, the number decreased by 35.2%, the maximum reduction rate, compared with before treatment. However, the number of lesions at any given time point was not significantly different when compared with the following time point, except for the first assessment versus the second one. In regard to inflammatory lesions, we could observe a continuous, significant improvement throughout the study period (Fig. 3). The average reduction rate reached 77.9% by the end of the study. Statistically significant changes were found between the 1st and 2nd, 2nd and 3rd, and 5th and 6th assessments. The number of acne scars remained unchanged in all subjects, so it was omitted from any statistical analysis. Figure 4 concisely presents the

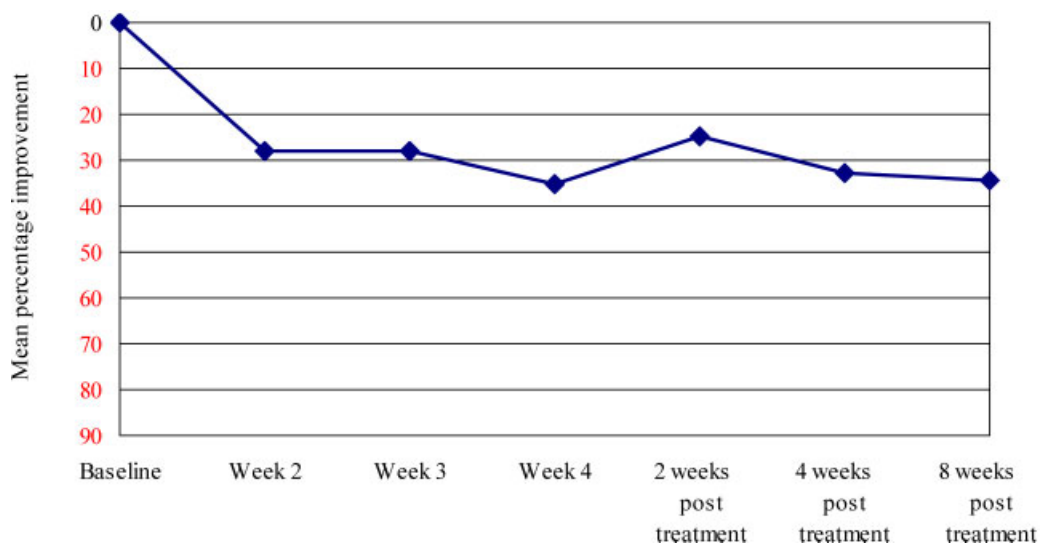


Fig. 2. Mean percentage improvement in non-inflammatory lesions (closed and open comedones).

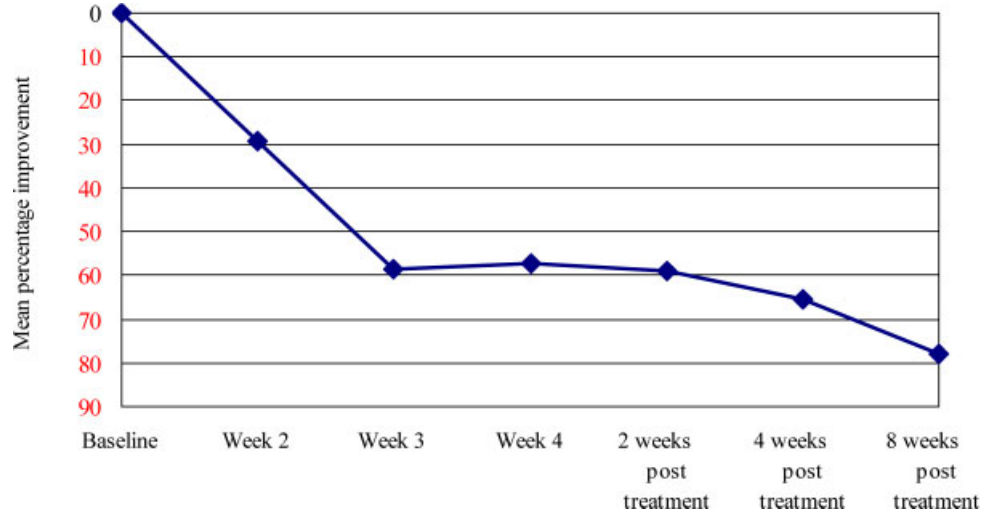


Fig. 3. Mean percentage improvement in inflammatory lesions (papules, pustules, nodules or cysts).

numbers of each type of lesion at the baseline and at the last assessment. A paired *t*-test was used to evaluate the differences between the two time points, which confirmed the previous statistical results.

The investigator's global assessment indicated that the number of patients who showed marked improvement (> 60% improvement compared to the baseline) was 12 out of 24 (50%) after four treatments, while it was 21 (87.5%) at 8 weeks after the treatment completion (Fig. 5A). The treatment effectiveness appeared more obviously as time passed, including the treatment-free follow-up period. In one female patient, her acne lesions had improved until 2 weeks post treatment, but was aggravated again in her premenstrual period to return to the baseline status at 4 weeks post treatment, which is indicated as "no change" in Figure 5A. At the end of the follow-up period, clearance of acne (> 90% improvement) was achieved in two patients.

As for the subject's global assessment, 11 patients (45.8%) expressed their satisfaction with the treatment as "good" or "excellent" after four treatments, while 18 patients (75%) did so at the 8 weeks post treatment (Fig. 5B). At the mid-point assessment, 10 patients reported that there was no change or even worsening in their acne, 2 of whom finally found no advantage by the end of the study.

None of the subjects reported any adverse reaction related to the treatment. Some patients commented on mild warmth during red light irradiation, which they felt as comfortable. Fourteen patients (58.3%) spontaneously reported brightening of skin tone and improvement of skin texture after the treatment, which raised their satisfaction level with the treatment.

Instrumental Measurements

The moisture and sebum levels were not significantly different between before and after treatment, though they showed a tendency to decrease slightly. The melanin level,

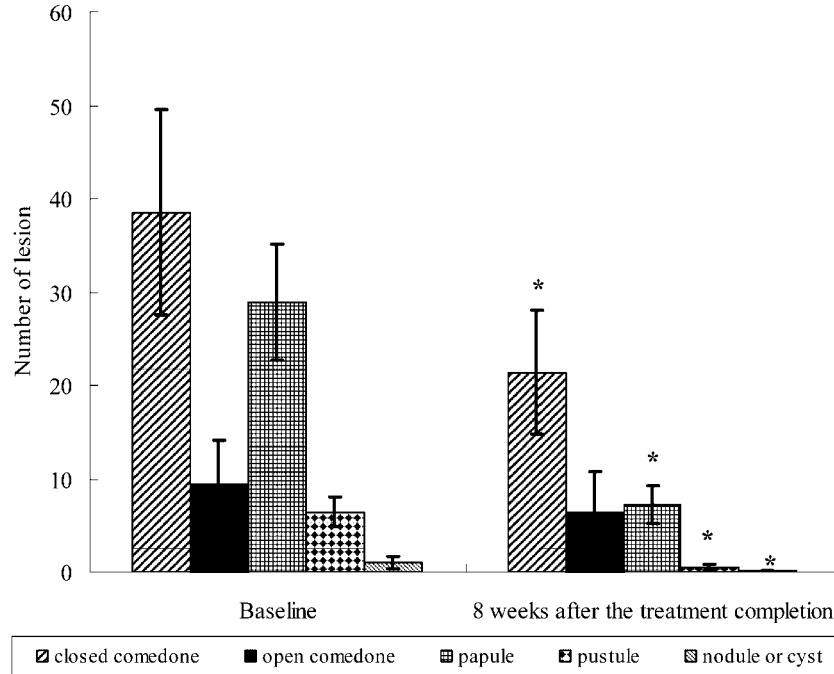
however, decreased significantly after treatment ($P < 0.005$) with a median of differences of -7.08 (Table 2). An additional statistical analysis was done to find out which wavelength of light had affected the melanin level more strongly (Table 3). It revealed that the melanin level increased by 6.7 (the median of differences between before and after one treatment session) after blue light irradiation without a statistical significance (P -value > 0.1), whereas it decreased by 15.5 with a statistical significance (P -value < 0.005) after red light irradiation.

DISCUSSION

The pathogenesis of acne has not yet been clarified. It is the current consensus that acne is a multifactorial disease which involves four primary events; follicular hypercornification, increased sebum secretion, colonization of *P. acnes*, and inflammation [14]. Particularly, *P. acnes* is considered to play a key role in more than one way. It acts on triglycerides and releases its cytokines, which trigger inflammatory reactions and also alter the infundibular keratinization status [19,32].

Recently, it has been proved that the bacterial porphyrins, which *P. acnes* produces as a part of its normal metabolism, can cause a photodynamic reaction with exposure to absorbed wavelengths of light. This reaction stimulates production of reactive free radicals and singlet oxygen species, which results in destruction of the bacteria [14–23]. Although the bacterial sensitivity to light becomes higher as the wavelength gets shorter, there exists a second absorption peak at 415 nm, which corresponds to that of coproporphyrin III, the predominant bacterial porphyrin produced by *P. acnes* [15,21,33,34].

Many clinical studies have proved the efficacy of blue light in the treatment of acne [24–31]. Among them, a unique clinical study performed by Papageorgiou et al. [24] tried the mixture of blue and red light from fluorescent



* Statistically significant

Type of lesion	Baseline	8 weeks after the treatment completion	p-value [†]
Closed comedone	38.54±26.08	21.42±15.87	0.0007
Open comedone	9.46±10.97	6.42±10.27	0.0752
Papule	28.92±14.66	7.17±4.79	<.0001
Pustule	6.46±3.95	0.50±0.83	<.0001
Nodule or cyst	1.04±1.57	0.13±0.45	0.0029

† : P-values are for paired t-test

Fig. 4. The numbers of each type of lesions at baseline and at the 8-week post treatment assessment (with numerical data shown in the table).

lamps for acne, which showed mean percentage improvements in comedones and inflammatory lesions of 58% and 76%, respectively. These clearance rates were significantly higher than those with blue light therapy alone. The authors proposed that the superior effect of the mixed light was due to the synergy between the anti-bacterial and anti-inflammatory effect of blue and red light, respectively.

The beneficial effects of red light on the skin have been suggested by many studies [35–45]. It has been demonstrated by an in vitro study that red light influenced cytokine release from macrophages, which consequently stimulated fibroblast proliferation [35]. Karu [38,39] suggested that absorption of red and near-infrared light by photoacceptor molecules within the respiratory chains can cause alteration in the redox status of the cells and activate the nucleic acid synthesis to accelerate cell proliferation. Additionally, Lanzafame and his colleagues showed that low-level laser irradiation at a wavelength

within visible red waveband can produce various beneficial effects such as stimulation of cell proliferation, release of growth factors, collagen deposition, and neovascularization [40–42].

Recently, the LED has become of interest to many investigators as a new light source for phototherapy. A series of comprehensive studies performed by Whelan et al. [43–45] demonstrated that 670 nm LED treatment upregulated tissue regeneration genes and accelerated wound closure. Their study also showed that the expression of genes coding cytokines and their receptors was down-regulated after red LED treatment. In addition to the wound healing enhancement, photorejuvenation, which refers to the process where light is used to improve photoaged skin, has been proposed as another application of LED by Weiss et al. [46–49] (590 nm) and Russell et al. [50] (633 and 830 nm). The use of blue LEDs in the treatment of acne was reported by Morton et al. [30], which

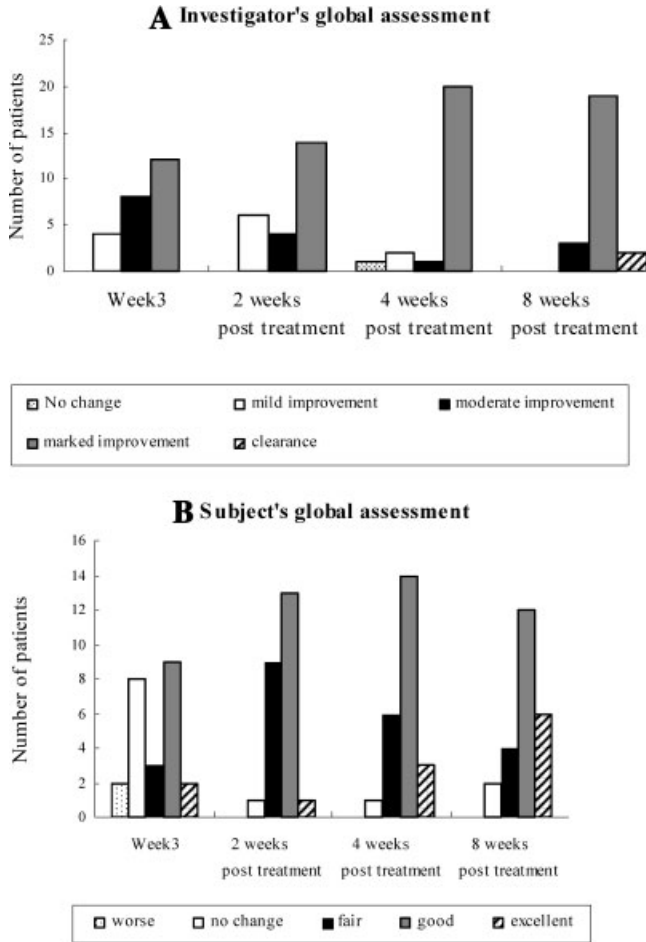


Fig. 5. The investigator's (A) and the subject's (B) global assessment.

showed a good treatment effect on inflammatory acne lesions. Although the exact mechanisms of action have not yet been clarified, LEDs are considered to be highly effective in enhancing cellular activities through mitochondrial photobiomodulation (visible red waveband) as well as in eliciting the photodynamic destruction of *P. acnes* (visible blue waveband) [30,45].

In the present study, we treated patients with facial acne by alternating blue light treatment and red light treatment, utilizing a high intensity LED-based device, which had very narrow-band wavelengths peaking at 415 and

633 nm, without any UV radiation at all, and a relatively low heat-emitting property. Our results showed final mean percentage improvements in comedones and inflammatory lesions of 34.28% and 77.93%, respectively. The superior effect on inflammatory lesions over comedones was noted in our study, in concordance with other clinical trials using blue light treatment [16,19,24,26]. This tendency might be caused by the fact that *P. acnes*, the main target of light therapy, resides mostly in inflammatory acne lesions [51]. The mean percentage improvement of inflammatory lesions was similar to that of Papageorgiou's study [24] where the mixture of blue and red light was used (76%), but higher than those where blue light was used alone such as Gold et al. [31] (36%), Elman et al. [27] (59–67%), Morton et al. [30] (64%), Kawada et al. [26] (papule:69.3%, pustules: 73.3%), and Tzung et al. [28] (approximately 60% improvement in papulopustular lesions and 20% aggravation in nodulocystic lesions, exact numerical data not provided). It was notable that the nodulocystic lesions responded to our treatment as well, whereas they were aggravated in Tzung's study [28] where blue light was used alone. This result suggests that combining red light with blue light may exert a synergistic effect between anti-inflammatory and anti-bacterial action, respectively, to improve extremely inflamed acne lesions.

We consider the mean percentage improvement of acne lesions presented in our study is high enough to be comparable to the efficacy of photodynamic therapy using aminolevulinic acid (abbreviated as ALA-PDT). ALA-PDT can be beneficial for acne particularly because it destroys pilosebaceous units as well as *P. acnes* [52–54]. Although its efficacy has been reported with variable mean percentage reduction rates from 32% to 72% according to different authors [55–62], ALA-PDT would not appear to offer significant advantage in the treatment of acne, particularly when the adverse effects of considerable long-lasting post inflammatory hyperpigmentation (PIH) following severe acute local reactions are taken into account, which is especially the case in dark-skinned individuals of Asian origin [19,55,58–62]. In addition, the time lapse for ALA incubation and the necessity of vigorous sun protection to avoid potential phototoxic reactions for several days after ALA-PDT may decrease the patients' satisfaction level regarding this therapy [19].

The instrumental measurement results gave an interesting finding, in that the melanin level decreased significantly after the red light irradiation, whereas with blue light, the level increased slightly. However, combining

TABLE 2. Differences in the Moisture Level, the Sebum Level, and the Melanin Level Between Before and After Treatment

Type of instrumental measurement	Difference		P-value (Sign rank test)
	Mean \pm std	Median	
Corneometer TM (moisture)	-0.81 \pm 4.34	-1.42	0.3264
Sebumeter TM (sebum)	-13.88 \pm 56.88	-5.25	0.2502
Mexameter TM (melanin)	-5.69 \pm 8.38	-7.08	0.0032

TABLE 3. The Differences in the Melanin Level After Each Blue and Red Light Irradiation, and After the Final Treatment Compared With Before the First Treatment

Variables	Difference		<i>P</i> -value
	Mean \pm std	Median	
Between before and after each blue light irradiation	8.52 \pm 15.48	6.70	0.3125 ^a
Between before and after each red light irradiation	-17.97 \pm 13.62	-15.50	0.0020 ^a
Between before the first treatment and after the final treatment	-17.79 \pm 18.60	-16.20	0.0001 ^b

^a*P*-values are for sign rank test.

^b*P*-value is for paired *t*-test.

both wavelengths of light produced an overall decrease in the melanin level, which reached a statistically significant level. We compared the melanin levels taken before the first treatment with those taken after the last treatment (Table 3). The paired *t*-test revealed a significant reduction of melanin levels by -17.79 ± 18.60 after the last treatment (*P*-value = 0.0001) compared to the baseline. To the best of our knowledge, no study has to date reported on the differences in instrumentally measured melanin levels between before and after red light irradiation. It is possible that this finding has some relationship with the brightening effect of the skin tone, which 14 out of 24 patients spontaneously reported after the treatment period. The mechanism of red light affecting the melanin level is not clear and remains to be determined by further studies. In regards to the moisture and sebum levels, the results showed an insignificant decrease in both. Therefore, it may be helpful to apply moisturizer after each treatment. It is highly possible that the decrease in the moisture level is due to the mild heat emitted from the phototherapy device.

The investigator's and the subject's assessment showed a tendency for the latter to express less satisfaction than the former, even though the proportion of subjects who answered "good" or "excellent" increased throughout the study period. At the mid-point assessment, 10 patients reported that they could not find any improvement in their acne. Two of them complained of a transient, mild flare-up of previous acne lesions after the blue light treatments, which did not occur after red light treatment. A possible explanation for this phenomenon is that the debris of destroyed *P. acnes* may initiate an inflammatory response by recruiting neutrophils and stimulating the release of complements [55,63,64]. The temporary eruption disappeared spontaneously after 1–2 days. At the end of the study, only two patients expressed their dissatisfaction with the treatment. However, the number of acne lesions in these patients actually turned out to have decreased by lesion counting, which encouraged us to make further inquiries at the last assessment to find out the reasons for the differences in satisfaction levels between the investigator and the subjects. The result revealed that the patients were unsatisfied because of the erythema and PIH on their previous acne sites. This is a typical pitfall in the treatment of acne of dark-skinned individuals, which is sometimes regarded as a treatment failure by the patients [65,66]. Therefore, proper management of PIH is sug-

gested to be combined with this LED phototherapy, especially for Asian patients and other dark-skinned individuals, as it is also the case with other acne treatment modalities.

There was no side effect reported regarding this therapy during the whole study period except a sense of mild warmth during the red light treatment, which, however, the patients had felt as comfortable. Recently, several clinical studies have shown that heat may be beneficial for acne [67–70], which raises a possibility for our subjects to have benefited from the mild heat from the LED device. However, the devices used in those studies were specifically designed to deliver thermal energy to the dermis while used in contact with the skin surface, whereas the one used for our study was equipped with cooling fans to avoid heat generation, consisted of LEDs which have low heat-emitting property, and was positioned 3–5 cm above from the skin surface during the treatment. We measured the skin surface temperature before and after treatment with a digital infrared thermometer (Dotory PlusTM, HuBDIC Co., Ltd., Anyang, Republic of Korea), the difference of which turned out to be only about 1°C. Therefore, we consider that, in the present study, the amount of heat which actually reached the dermis should be too small to produce significant therapeutic effects.

Our treatment method for acne, alternating blue and red LED phototherapy, was easy to deliver, well-tolerated, pain- and side-effect free, and gave a satisfyingly high clearance rate in patients with inflammatory acne. The study has, however, several limitations. There was no control group using either classical treatment modalities or other previously reported phototherapy methods with blue light alone or a mixture of blue and red light. The small sample size and the relatively short follow-up period should also be considered as limitations to this study. However, the high percentage of clearance in inflammatory acne at the 8-week post treatment assessment, and the concordance of this result with other studies, mean that further investigation through controlled, randomized, and blinded studies is merited to determine the efficacy and to optimize the treatment parameters for blue and red light combination LED phototherapy.

CONCLUSIONS

We treated 24 patients with mild to moderately severe facial acne using quasimonochromatic LED devices,

alternating blue (415 nm) and red (633 nm) light. The final mean percentage improvements in non-inflammatory and inflammatory lesions were 34.28% and 77.93%, respectively. No adverse effect was found after treatment. Brightened skin tone and improved skin texture were spontaneously reported by 14 patients. Objective instrumental measurements indicated that the melanin levels significantly decreased by -17.79 ± 18.60 after the eighth treatment, compared to those measured before the first treatment (P -value = 0.0001). We consider that this blue and red light combination LED phototherapy is an effective, safe, pain-free, and easy-to-perform treatment for mild to moderately severe acne vulgaris, particularly for inflammatory lesions. The newly found brightening effect of this therapy would be appealing to Asians, although the exact efficacy and mechanism of this effect need further investigations.

ACKNOWLEDGMENTS

We wish to thank Photo Therapeutics Ltd., Fazely, Tamworth, UK, for generously making available the LED-based OmniluxTM devices used in this study at no cost. We are also deeply grateful to Antonius R. Soelistyo, B. Tech (hons), for his kindness to help us with performing this study, and to R. Glen Calderhead, MA, DrSci, FRSM, for the English proofreading of this paper.

REFERENCES

- Leyden JJ. Therapy for acne vulgaris. *N Engl J Med* 1997; 336:1156–1162.
- Mulder MMS, Sigurdsson V, van Zuuren EJ, Klaassen EJ, Faber JAJ, de Wit JBF, et al. Psychosocial impact of acne vulgaris. Evaluation of the relation between a change in clinical acne severity and psychosocial state. *Dermatology* 2001;203:124–130.
- Burton JL, Cunliffe WJ, Stafford I, Shuster S. The prevalence of acne vulgaris in adolescence. *Br J Dermatol* 1971;85:119–126.
- Pawin H, Beylot C, Chivot M, Faure M, Poli F, Revuz J, et al. Physiopathology of acne vulgaris: Recent data, new understanding of the treatments. *Eur J Dermatol* 2004;14: 4–12.
- Longshore SJ, Hollandsworth K. Acne vulgaris: One treatment does not fit all. *Cleve Clin J Med* 2003;70:672–674.
- Gollnick HP, Krauthaim A. Topical treatment in acne: Current status and future aspects. *Dermatology* 2003;206: 29–36.
- Eady EA, Jones CE, Tipper JL, et al. Antibiotic resistant propionibacteria in acne: Need for policies to modify antibiotic usage. *BMJ* 1993;306:555–556.
- Eady EA. Bacterial resistance in acne. *Dermatology* 1998; 196:59–66.
- Coates P, Vyakrnam S, Eady EA, Jones CE, Cove JH, Cunliffe WJ. Prevalence of antibiotic-resistant propionibacteria on the skin of acne patients: 10-year surveillance data and snapshot distribution study. *Br J Dermatol* 2002;146: 840–848.
- Cooper AJ. Systemic review of *Propionibacterium acnes* resistance to systemic antibiotics. *Med J Aust* 1998;169: 259–261.
- Stern RS. When a uniquely effective drug is teratogenic: The case of isotretinoin. *New Engl J Med* 1989;320:1007–1009.
- Hull PR, D'Arcy C. Isotretinoin use and subsequent depression and suicide: Presenting the evidence. *Am J Clin Dermatol* 2003;4:493–505.
- Kaminsky A. Less common methods to treat acne. *Dermatology* 2003;206:68–73.
- Charakida A, Seaton ED, Charakida M, Mouser P, Avgerinos A, Chu AC. Phototherapy in the treatment of acne vulgaris: What is its role? *Am J Clin Dermatol* 2004;5:211–216.
- Kjeldstad B, Johnsson A. An action spectrum for blue and near ultraviolet inactivation of *Propionibacterium acnes*; with emphasis on a possible porphyrin photosensitization. *Photochem Photobiol* 1986;43:67–70.
- Sigurdsson V, Knulst AC, van Weelden H. Phototherapy of acne vulgaris with visible light. *Dermatology* 1997;194:256–260.
- Cunliffe WJ, Goulden V. Phototherapy and acne vulgaris. *Br J Dermatol* 2000;412:855–856.
- Elman M, Lebzelter J. Light therapy in the treatment of acne vulgaris. *Dermatol Surg* 2004;30:139–146.
- Ross EV. Optical treatments for acne. *Dermatol Ther* 2005; 18:253–266.
- Bhardwaj SS, Rohrer TE, Arndt K. Lasers and light therapy for acne vulgaris. *Semin Cutan Med Surg* 2005;24:107–112.
- Arakane K, Ryu A, Hayashi C, Masunaga T, Shinmoto K, Mashiko S, et al. Singlet oxygen (1 delta g) generation from coproporphyrin in *Propionibacterium acnes* on irradiation. *Biochem Biophys Res Commun* 1996;223:578–582.
- Ashkenazi H, Malik Z, Harth Y, Nitzan Y. Eradication of *Propionibacterium acnes* by its endogenous porphyrins after illumination with high intensity blue light. *FEMS Immunol Med Microbiol* 2003;35:17–24.
- Futsaether CM, Kjeldstad B, Johnsson A. Intracellular pH changes induced in *Propionibacterium acnes* by UVA radiation and blue light. *J Photochem Photobiol B* 1995;31:125–131.
- Papageorgiou P, Katsambas A, Chu A. Phototherapy with blue (415 nm) and red (660 nm) light in the treatment of acne vulgaris. *Br J Dermatol* 2000;142:973–978.
- Ammad S, Edwards C, Gonzalez M, Mills CM. The effect of blue light phototherapy on mild to moderate acne. *Br J Dermatol* 2002;147(Suppl. 62):95.
- Kawada A, Aragane Y, Kameyama H, Sangen Y, Tezuka T. Acne phototherapy with a high-intensity, enhanced, narrow-band, blue light source: An open study and *in vitro* investigation. *J Dermatol Sci* 2002;30:129–135.
- Elman M, Slatkine M, Harth Y. The effective treatment of acne vulgaris by a high-intensity, narrow band 405–420 nm light source. *J Cosmet Laser Ther* 2003;5:111–116.
- Tzung TY, Wu KH, Huang ML. Blue light phototherapy in the treatment of acne. *Photodermatol Photoimmunol Photomed* 2004;20:266–269.
- Omi T, Bjerring P, Sato S, Kawada S, Hankins RW, Honda M. 420 nm intense continuous light therapy for acne. *J Cosmet Laser Ther* 2004;6:156–162.
- Morton CA, Scholefield RD, Whitehurst C, Birch J. An open study to determine the efficacy of blue light in the treatment of mild to moderate acne. *J Dermatol Surg* 2005;16:219–223.
- Gold MH, Rao J, Goldman MP, Bridges TM, Bradshaw VL, Boring MM, et al. A multicenter clinical evaluation of the treatment of mild to moderate inflammatory acne vulgaris of the face with visible blue light in comparison to topical 1% clindamycin antibiotic solution. *J Drugs Dermatol* 2005;4: 64–70.
- Leyden JJ, McGinley KJ, Mills OH, Kligman AM. Propionibacterium levels in patients with and without acne vulgaris. *J Invest Dermatol* 1975;65:382–384.
- Cornelius CE III, Ludwig GD. Red fluorescence of comedones: Production of porphyrins by *Corynebacterium acnes*. *J Invest Dermatol* 1967;49:368–370.
- Lee WL, Shalita AR, Poh-Fitzpatrick MB. Comparative studies of porphyrins production in *Propionibacterium acnes* and *Propionibacterium granulosum*. *J Bacteriol* 1978;133: 811–815.
- Young S, Bolton P, Dyson M, Harvey W, Diamantopoulos C. Macrophage responsiveness to light therapy. *Lasers Surg Med* 1989;9:497–505.

36. Lam TS, Abergel RP, Meeker CA, Castel JC, Dwyer RM, Uitto J. Laser stimulation of collagen synthesis in human skin fibroblast cultures. *Laser Life Sci* 1986;1:61–77.
37. Schindl A, Schindl M, Schön H, Knobler R, Havelec L, Schindl L. Low-intensity laser irradiation improves skin circulation in patients with diabetic microangiopathy. *Diabetes Care* 1998;21:580–584.
38. Karu TI. Photobiological fundamentals of low-power laser therapy. *J Quantum Electron* 1987;23:1703–1717.
39. Karu T. Primary and secondary mechanisms of action of visible to near-IR radiation on cells. *J Photochem Photobiol B* 1999;49:1–17.
40. Stadler I, Evans R, Kolb B, Naim JO, Narayan V, Buehner N, et al. *In vitro* effects of low-level laser irradiation at 660 nm on peripheral blood lymphocytes. *Lasers Surg Med* 2000;27:255–261.
41. Yu W, Naim JO, Lanzafame RJ. Effects of photostimulation on wound healing in diabetic mice. *Lasers Surg Med* 1997;20:56–63.
42. Yu W, Naim JO, Lanzafame RJ. The effect of laser irradiation on the release of bFGF from 3T3 fibroblasts. *Photochem Photobiol* 1994;59:167–170.
43. Whelan HT, Smits RL, Jr., Buchman EV, Whelan NT, Turner SG, Margolis DA, et al. Effect of NASA light-emitting diode irradiation on wound healing. *J Clin Laser Med Surg* 2001;19:305–314.
44. Whelan HT, Connelly JF, Hodgson BD, Barbeau L, Post AC, Bullard G, et al. NASA light-emitting diodes for the prevention of oral mucositis in pediatric bone marrow transplant patients. *J Clin Laser Med Surg* 2002;20:319–324.
45. Whelan HT, Buchman EV, Dhokalia A, Kane MP, Whelan NT, Wong-Riley MT, et al. Effect of NASA light-emitting diode irradiation on molecular changes for wound healing in diabetic mice. *J Clin Laser Med Surg* 2003;21:67–74.
46. Weiss RA, Weiss MA, Beasley KL, Munavalli G. Our approach to non-ablative treatment of photoaging. *Lasers Surg Med* 2005;37:2–8.
47. Weiss RA, McDaniel DH, Geronemus RG, Weiss MA. Clinical trial of a novel non-thermal LED array for reversal of photoaging: Clinical, histologic, and surface profilometric results. *Lasers Surg Med* 2005;36:85–91.
48. Weiss RA, McDaniel DH, Geronemus RG, Weiss MA, Beasley KL, Munavalli GM, et al. Clinical experience with light-emitting diode (LED) photomodulation. *Lasers Surg Med* 2005;31:1199–1205.
49. Weiss RA, Weiss MA, Geronemus RG, McDaniel DH. A novel non-thermal non-ablative full panel LED photomodulation device for reversal of photoaging: Digital microscopic and clinical results in various skin types. *J Drugs Dermatol* 2004;3:605–610.
50. Russell BA, Kellett N, Reilly LR. A study to determine the efficacy of combination LED light therapy (633 nm and 830 nm) in facial skin rejuvenation. *J Cosmet Laser Ther* 2005;7:196–200.
51. Webster GF. Inflammation in acne vulgaris. *J Am Acad Dermatol* 1995;33:247–253.
52. Nitzan Y, Kauffman M. Endogenous porphyrin production in bacteria by δ -aminolevulinic acid and subsequent bacterial photoeradication. *Lasers Med Sci* 1999;14:269–277.
53. Inuma S, Farshi SS, Ortel B, Hasan T. A mechanistic study of cellular photodestruction with 5-aminolevulinic acid-induced porphyrin. *Br J Cancer* 1994;79:21–28.
54. Ramstad S, Futsaether CM, Johnson A. Porphyrin sensitization and intracellular calcium changes in the prokaryote, *Propionibacterium acnes*. *J Photochem Photobiol B* 1997;40:141–148.
55. Hongcharu W, Taylor CR, Chang Y, Aghassi D, Suthamjariya K, Anderson RR. Topical ALA-photodynamic therapy for the treatment of acne vulgaris. *J Invest Dermatol* 2000;115:183–192.
56. Itoh Y, Ninomiya Y, Tajima S, Ishibashi A. Photodynamic therapy for acne vulgaris with topical 5-aminolevulinic acid. *Arch Dermatol* 2000;136:1093–1095.
57. Itoh Y, Ninomiya Y, Tajima S, Ishibashi A. Photodynamic therapy of acne vulgaris with topical δ -aminolevulinic acid and incoherent light in Japanese patients. *Br J Dermatol* 2001;144:575–579.
58. Pollock B, Turner D, Stringer M, Bojar RA, Goulden V, Stables GI, et al. Topical aminolevulinic acid-photodynamic therapy for the treatment of acne vulgaris: A study of clinical efficacy and mechanism of action. *Br J Dermatol* 2004;151:616–622.
59. Hong SB, Lee MH. Topical aminolevulinic acid-photodynamic therapy for the treatment of acne vulgaris. *Photodermatol Photoimmunol Photomed* 2005;21:322–325.
60. Uebelhoefer NS, Dover JS. Photodynamic therapy for cosmetic applications. *Dermatol Ther* 2005;18:242–252.
61. Morton CA, Brown SB, Collins S, Ibbotson S, Jenkinson H, Kurwa H, et al. Guidelines for topical photodynamic therapy: Report of a workshop of the British photodermatology group. *Br J Dermatol* 2002;146:552–567.
62. Gupta AD, Ryder JE. Photodynamic therapy and topical aminolevulinic acid. *Am J Clin Dermatol* 2003;4:699–708.
63. Webster GF, Leyden JJ, Tsai CC, Bachni R, McArthur WP. Polymorphonuclear leukocyte liposomal release in response to *Propionibacterium acnes* and its enhancement by sera from inflammatory acne patients. *J Invest Dermatol* 1986;74:398–401.
64. Vowels B, Yang S, Leyden JJ. Induction of proinflammatory cytokines by a soluble factor of *Propionibacterium acnes*: Implications to chronic inflammatory acne. *Infect Immunol* 1995;63:3158–3165.
65. Callender VD. Considerations for treating acne in ethnic skin. *Cutis* 2005;76:19–23.
66. Grimes P, Callender V. Tazarotene cream for postinflammatory hyperpigmentation and acne vulgaris in darker skin: A double-blind, randomized, vehicle-controlled study. *Cutis* 2006;77:45–50.
67. Elman M, Lask G. The role of pulsed light and heat energy (LHETM) in acne clearance. *J Cosmet Laser Ther* 2004;6:91–95.
68. Prieto VG, Zhang PS, Sadick NS. Evaluation of pulsed light and radiofrequency combined for the treatment of acne vulgaris with histologic analysis of facial skin biopsies. *J Cosmet Laser Ther* 2005;7:63–68.
69. Ruiz-Esparza J, Gomez JB. Nonablative radiofrequency for active acne vulgaris: The use of deep dermal heat in the treatment of moderate to severe active acne vulgaris (thermotherapy): A report of 22 patients. *Dermatol Surg* 2003;29:333–339.
70. Paithankar DY, Ross EV, Saleh BA, Blair MA, Graham BS. Acne treatment with a 1,450 nm wavelength laser and cryogen spray cooling. *Lasers Surg Med* 2002;31:106–114.